



PATIENT

Teddy Gramm
Stoudemire

PRESENTING CLINICAL SIGNS

History: Recheck echo.
-Pertinent previous echo findings (9/2021 MML): Moderate + PS, rule valvular versus R2A. Mild RHE, trace TR.

SPECIES

Canine

ECHOCARDIOGRAM FINDINGS

2D, m-mode, color flow and doppler imaging is available. Normal mitral valve leaflets with no obvious prolapse into the left atrial lumen. No mitral regurgitation. Normal left atrial dimension. Normal LV diameter with normal myocardial function. The LV wall is normal. The tricuspid valve appears normal with trace tricuspid regurgitation present. Mild right atrial dilation. Moderate to severe right ventricular hypertrophy and remodeling indicative of pressure overload. Mild right ventricular dilation. At least moderate elevation of pulmonic outflow velocities at the level of the valve. The pulmonic valve appears thickened and stenotic consistent with a valvular stenosis. Mild post-stenotic dilation. Mild pulmonic insufficiency. The aortic valve appears to have normal morphology and mobility. No AI. No obvious cardiac shunts are visualized. No pericardial or pleural effusion noted.

BREED

French Bulldog

SEX

Male

AGE

3 years

CARDIAC CHART

WEIGHT

27lbs

INTERPRETED BY

Maggie Machen Lamy,
DVM, DACVIM
(Cardiology)

CANINE CARDIAC PARAMETERS	MR VMAX (m/s)	TR VMAX (m/s)	LA/AO (Boon method)	LA/AO (Heart Base; Swe)	FS (%)	EF (%)	EPSS (cm)
NORMAL PARAMETER	4.5-5.5	<2.7	1.3	<1.6	28-40	40-100	<0.6
PATIENT	NA	NM	NM	1.3	34	65	0.2
CANINE CARDIAC PARAMETERS	HR (BPM)	AV VMAX (m/s)	PV MAX (m/s)	BODY WEIGHT (kg)	LA 2D short axis Base view (cm)	LVIDd Avg; 2D and m-mode short axis (cm)	LVIDs Avg; 2D and m-mode short axis (cm)
NORMAL PARAMETER	50-100	0.7-1.7	0.7-1.6	BELOW	BELOW	BELOW	BELOW
PATIENT	130	1.6	>4.0	12.2	2.0	2.9	1.9
*Normal chamber parameters expressed as a mean value (SD)				3	1.27 (5.3)	2.46 (2.46)	1.36 (5.5)
BODY WEIGHT DEPENDENT PARAMETERS				5	1.40 (4.5)	2.74 (5.2)	1.60 (4.7)
<i>*Note: All measurements based upon multi-modal images and methods. An average value is reported.</i>				10	1.50 (3.8)	3.27 (3.5)	2.06 (3.1)
				15	1.83 (2.0)	3.71 (2.4)	2.43 (2.1)
				20	2.02 (1.9)	4.14 (2.2)	2.80 (2.0)
				25	2.18 (2.4)	4.48 (2.9)	3.10 (2.5)
				30	2.33 (3.3)	4.83 (3.9)	3.39 (3.4)
				35	2.48 (4.3)	5.17 (5.0)	3.69 (4.5)
				40	2.62 (5.2)	5.48 (6.1)	3.96 (5.4)
				50	2.88 (7.1)	6.07 (8.3)	4.46 (7.4)

Adapted from June Boon, Veterinary Echocardiography, 1998
Rishniw M and Hollis NE, J Vet Intern Med 2000; 14:429-435
Hansson et al, Vet Rad and Ultrasound 2002
Bonagura et al. Echocardiography: principles of interpretation, Vet Clin North Am 15:1177, 1995

HOSPITAL NAME

Double Churches
Animal Clinic

REFERRING VET

Dr. Boone

INVOICE

27820

DATE

12/5/22

INTERPRETATION OF THE FINDINGS & FURTHER RECOMMENDATIONS

Compared to the prior study, findings appear similar with **progressive right ventricular hypertrophy**. The velocity through the obstructive valve is similar and mild right atrial dilation unchanged. No obvious additional issues are identified.

Given these findings, lifelong Atenolol is recommended as previously discussed. It should be reiterated that this patient **should not be bred** due to the genetic link of this disease.



PATIENT

Teddy Gramm
Stoudemire

Monitor for development of associated clinical signs (collapse, abdominal distention, cough, labored breathing). Mild exercise restriction is advised. Omega fatty acid supplementation may have some long-term benefit, given these cases are predisposed to development of arrhythmias going forward.

SPECIES

Canine

Anesthetic risk is mild to moderate at this time. Avoid heart rate stimulating drugs such as atropine or glycopyrrolate unless absolutely necessary. Avoid vasodilators such as acepromazine. Mild IV fluid restriction is advised. Cardiac protective drug choices (opioid/benzodiazepine premedication, propofol or alfaxalone induction, isoflurane gas) are recommended. Pre-oxygenate for 5-10 minutes prior to induction and recover in O₂ if possible. Monitor for arrhythmias, hypotension, and hypoxia both intra and post-operatively and intervene as necessary.

BREED

French Bulldog

SEX

Male

PLAN

Consider referral for evaluation/surgical consultation as previously discussed > Administer Atenolol 25mg tabs, give ½ tab PO q12. Recheck HR in 5-7 days; target is stressed in hospital rates not to exceed 130bpm.

AGE

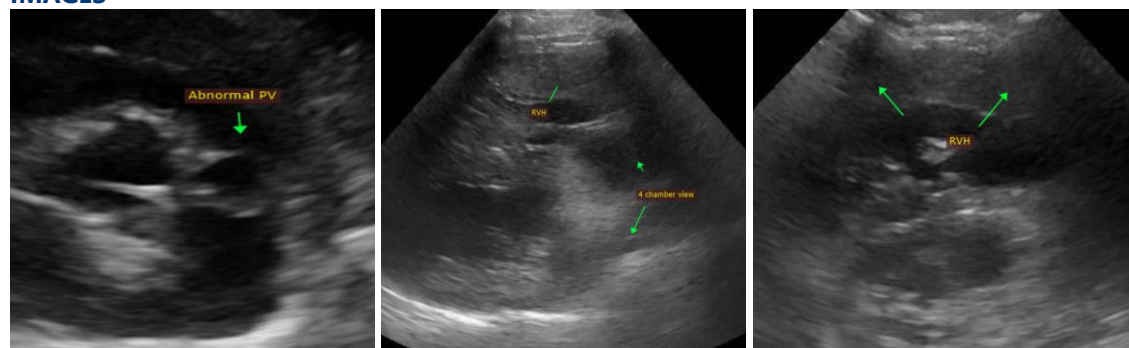
3 years

Recommend recheck echocardiogram annually, sooner if clinical signs arise.

WEIGHT

27lbs

IMAGES



INTERPRETED BY

Maggie Machen Lamy,
DVM, DACVIM
(Cardiology)

IMAGING PERFORMED BY

Lindsey Daniel, DVM

HOSPITAL NAME

Double Churches
Animal Clinic

The information and recommendations provided are based on the images presented by the referring veterinarian. No evaluation can be communicated regarding pathology that was not visible in the image/video clips provided.

REFERRING VET

Dr. Boone

Thank you for this referral. This report was generated using transcription software, and minor dictation errors may be present. If the clinical or image interpretation does not parallel your findings or if I can be of any further assistance, please contact me.

INVOICE

27820

Maggie Machen Lamy, DVM

Diplomate of the American College of Veterinary Internal Medicine (Cardiology)

info@sonopath.com

DATE

12/5/22



PATIENT

Teddy Gramm
Stoudemire

SPECIES

Canine

BREED

French Bulldog

SEX

Male

AGE

3 years

WEIGHT

27lbs

INTERPRETED BY

Maggie Machen Lamy,
DVM, DACVIM
(Cardiology)

**IMAGING
PERFORMED BY**

Lindsey Daniel, DVM

HOSPITAL NAME

Double Churches
Animal Clinic

REFERRING VET

Dr. Boone

INVOICE

27820

DATE

12/5/22